

Content available at: <https://www.ipinnovative.com/open-access-journals>

IP International Journal of Medical Paediatrics and Oncology

Journal homepage: <https://www.ijmpo.com/>

## Case Report

# Tolosa-Hunt syndrome – A case of treatable headache

Ananda T M Kesavan<sup>1,\*</sup>, Suma Premanandan<sup>1</sup>, Abdul N Basith<sup>1</sup>

<sup>1</sup>Dept. of Pediatrics, Govt. Medical College, Thrissur, Kerala, India



### ARTICLE INFO

#### Article history:

Received 21-06-2021

Accepted 07-09-2021

Available online 14-10-2021

#### Keywords:

TolosaHunt Syndrome

Ophthalmoplegia

headache

### ABSTRACT

Tolosa-Hunt Syndrome is characterised by headache and ophthalmoplegia due to involvement of third, fourth, sixth cranial nerve. The exact aetiology is not known. MRI brain is diagnostic test of choice. Treatment is mainly using corticosteroids. Prognosis is good with rapid recovery from headache and ophthalmoplegia. There are only few case reports Tolosa-Hunt Syndrome in children.

This is an Open Access (OA) journal, and articles are distributed under the terms of the [Creative Commons Attribution-NonCommercial-ShareAlike 4.0 License](https://creativecommons.org/licenses/by-nc-sa/4.0/), which allows others to remix, tweak, and build upon the work non-commercially, as long as appropriate credit is given and the new creations are licensed under the identical terms.

For reprints contact: [reprint@ipinnovative.com](mailto:reprint@ipinnovative.com)

## 1. Introduction

Tolosa-Hunt Syndrome (TTS) is characterised by headache and ophthalmoplegia due to involvement of third, fourth, sixth cranial nerve and sometimes ophthalmic branch of fifth cranial nerve.<sup>1</sup> The exact aetiology of THS is not known. Treatment is mainly using corticosteroids. There are only few case reports of THS in children. We are presenting a case of THS in a 12-year-old girl.

## 2. Case Report

A twelve-year-old girl, developmentally normal, immunized for age presented with headache of 7 days duration and vomiting of two days. Headache was of severe type, disturbing her sleep and daily activities. Headache was mainly over forehead. Next day, she developed double vision and drooping of eyelid of the left eye.

No history of fever, altered sensorium or seizure. No history of trauma. No history of other cranial nerve involvement or motor weakness. No family history of tuberculosis or any other significant illness in the past.

O/E: Child was fully conscious and active. Vitals were stable. No neuro cutaneous markers. Her all anthropometric

measurements were normal.

On nervous system examination: She was fully conscious and oriented. There was ptosis on left side with restricted lateral eye movement on the same side. She was also having decreased adduction on left side. Fundus exam was normal. No nystagmus. Pupils showed normal response. All other cranial nerves were normal. No focal deficits or sensory loss. No signs of meningeal irritation.

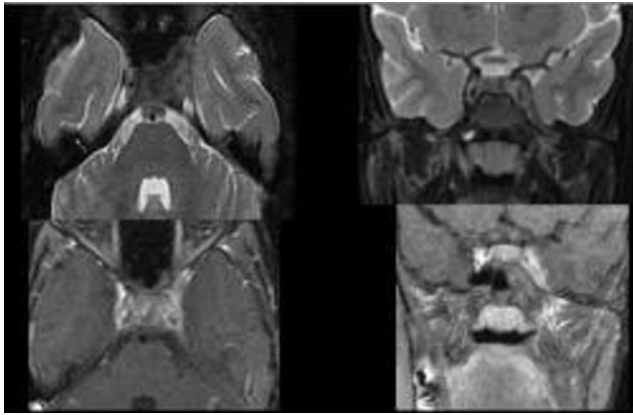
On investigation, her Hb was 12.7. Total leucocyte count was 17,300/mm<sup>3</sup>. Her ESR was 90mm/hr. Normal RFT and LFT. ANA and anti MPO antibody were negative. Sputum examination negative for evidence of tuberculosis. HIV and VDRL tests were non-reactive.

She was treated symptomatically. Lumbar puncture was done and CSF examination showed normal sugar and protein with 1-2 lymphocytes. In view of her persisting symptoms, MRI was done. MRI showed homogenous enhancing dural thickness involving left middle cranial fossa with inflammatory changes in left foramen ovale and adjacent medial pterygoid. Likely suggestive of idiopathic hypertrophic pachymeningitis. Brain parenchyma was normal (Figure 1).

Patient was started with intravenous dexamethasone for initial 4 days, followed by oral prednisolone (1mg/kg) for four weeks and then tapered slowly. Patient responded

\* Corresponding author.

E-mail address: [dranandiap@gmail.com](mailto:dranandiap@gmail.com) (A. T M Kesavan).



**Fig. 1:** MRI showed homogenous enhancing dural thickness involving left middle cranial fossa

well to the treatment. Headache subsided within 24 hrs of treatment. After 2 days her diplopia improved. On fifth day ptosis also disappeared with normal eye movements in all directions. On follow up after 2 months, she was asymptomatic.

On the basis of history, typical clinical features after excluding other possibilities and based on MRI findings and quick response to steroid, a diagnosis of Tolosa Hunt syndrome was made.

### 3. Discussion

Tolosa-Hunt syndrome is characterised by periorbital or hemicranial headache with varying degrees of ophthalmoplegia. Various combinations of cranial nerve involvement including ophthalmic division of fifth nerve localizing the lesion to the cavernous sinus or superior orbital fissure. It is necessary to exclude all other causes like trauma, neoplasm, aneurysm and inflammation in a case of THS. Dramatic response to steroid and characteristic MRI findings are also included in the criteria.

Tolosa described the syndrome 70 years back with headache, ophthalmoplegia and reduced sensation over the ophthalmic division of trigeminal nerve. Later it was found to be due to granulomatous inflammation of cavernous sinus.<sup>1</sup> Hunt described similar lesion independently, 7 years later.<sup>2</sup>

In 2013, Classification Committee of the International Headache Society (3rd edition, beta version), suggested the new criteria for diagnosis (Table 1).<sup>3</sup>

Clinical features last for days to weeks and remit spontaneously but rarely recur at intervals of months or years. Recurrences happen in 50% of cases and may be ipsilateral, contralateral, or rarely, bilateral cranial nerve palsy.<sup>4</sup> Very good response to steroid as in our case, is very characteristic. Smith and Taxdal were the first to apply the eponym “Tolosa-Hunt syndrome” and described utility of “steroid as a diagnostic test”.<sup>5</sup>

**Table 1:** Diagnostic criteria of THS, by ICHD-3 committee

A	Unilateral orbital or periorbital headache fulfilling criterion C
B	Both of the following: 1. granulomatous inflammation of the cavernous sinus, superior orbital fissure or orbit, demonstrated by MRI or biopsy 2. paresis of one or more of the ipsilateral III <sup>rd</sup> , IV <sup>th</sup> and/or VI <sup>th</sup> cranial nerves
C	Evidence of causation demonstrated by both of the following: 1. headache is ipsilateral to the granulomatous inflammation 2. headache has preceded paresis of the III <sup>rd</sup> , IV <sup>th</sup> and/or VI <sup>th</sup> nerves by $\leq 2$ weeks, or developed with it
D	Not better accounted for by another ICHD-3 diagnosis.

The disorder is rare during the first 2 decades of life and there are only very few case reports described in children.<sup>6,7</sup> Incidence is equal in both sex. The aetiology of Tolosa-Hunt syndrome remains unknown. What triggers the inflammatory process in the region of the cavernous sinus/superior orbital fissure is not known. It seems that the syndrome falls within the range of idiopathic orbital inflammation.<sup>8</sup>

Pathologically, Tolosa originally described non-specific, chronic inflammation with proliferation of fibroblasts and infiltration of the septa and wall of the cavernous sinus with lymphocytes and plasma cells. Subsequent reports have shown granulomatous inflammation, with epithelioid cells and occasional giant cells.<sup>2,9</sup>

Contrast enhanced MRI in coronal sections, is the most valuable diagnostic study. An area of abnormal soft tissue in the region of the cavernous sinus in most, but not all, patients with THS is seen. Typically, the abnormality is seen as an intermediate signal intensity on T1 images, consistent with an inflammatory process. With corticosteroid therapy, signal intensity will reverse in most reported cases.<sup>10</sup> The major limitation of MRI findings in THS is their lack of specificity.

THS is a diagnosis by exclusion. Investigation to rule out tumour, vascular causes, or other forms of inflammation in the region of the cavernous sinus/superior orbital fissure may be needed. Occasional reports have documented a raised erythrocyte sedimentation rate and leukocytosis in the acute stage of Tolosa-Hunt syndrome.<sup>11</sup> In this case also there was leucocytosis with high ESR.

Spontaneous remission is reported even before use of steroids, but steroid hastens the recovery. Headache subsides within 24hr of treatment with steroid. For refractory cases, azathioprine, methotrexate, or radiation therapy has been employed.<sup>12</sup> Because the diagnosis of THS is often made clinically, strict follow up must be maintained for the possibility of alternative masquerading diagnosis.

#### 4. Conclusion

THS should be suspected in all cases of headache and ophthalmoplegia. One has to rule out any other specific cause for similar pathology. MRI is the diagnostic test. Sterioid is the drug of choice. THS has good prognosis even though rarely it may recur.

#### 5. Conflict of Interest

The authors declare that there are no conflicts of interest in this paper.

#### 6. Source of Funding

None.

#### References

1. Tolosa E. Periarteritic lesions of the carotid siphon with the clinical features of a carotid infraclinoid aneurysm. *J Neurol Neurosurg Psychiatry*. 1954;17(4):300–2. doi:10.1136/jnnp.17.4.300.
2. Hunt WE, Meagher JN, Fever L, E H. Painful ophthalmoplegia. Its relation to indolent inflammation of the cavernous sinus. *Neurology*. 1961;11:56–62. doi:10.1212/wnl.11.1.56.
3. Headache Classification Committee of the International Headache Society (IHS). The International Classification of Headache Disorders, 3rd edition (beta version). *Cephalalgia*. 2013;33(9):629–808. doi:10.1177/0333102413485658.
4. Kline LB. The Tolosa-Hunt syndrome. *Surv Ophthalmol*. 1982;27(2):79–95. doi:10.1016/0039-6257(82)90190-4.
5. Smith JL, Taxdal DSR. Painful ophthalmoplegia. the Tolosa-Hunt syndrome. *Am J Ophthalmol*. 1966;61(6):1466–72.
6. Maria T, Michail G, Spyridon L, Pelagia V, Tolosa V. Tolosa-Hunt Syndrome: Clinical Manifestations in Children. *Pediatr Neurol*. 2019;99:60–3. doi:10.1016/j.pediatrneurol.2019.02.013.
7. Carlos AP, Monaliza E. Evaluation and Management of Tolosa-Hunt Syndrome in Children: A Clinical Update. *Pediatr Neurol*. 2016;62:18–26. doi:10.1016/j.pediatrneurol.2016.06.017.
8. Levy IS, Wright JE, Lloyd GAS. Orbital and retro-orbital pseudo-tumor. Modern Problems of. *Ophthalmology*. 1975;14:364–71.
9. Schatz NJ, Farmer P. Tolosa-Hunt syndrome: the pathology of painful ophthalmoplegia. In: Smith J, editor. Neuroophthalmology. Symposium of the University of Miami and the Bascom Palmer Eye Institute. vol. 6. St Louis: Mosby; 1972. p. 102–12.
10. Areaya AA, Cerezal L, Canga A. Neuroimaging diagnosis of Tolosa-Hunt syndrome: MRI contribution. *Headache*. 1999;39(5):321–5. doi:10.1046/j.1526-4610.1999.3905321.x.
11. Zafrulla KM, Dhir SP, Jain IS. Tolosa-Hunt syndrome. *Ind J Ophthalmol*. 1977;25(2):21–7.
12. Foubert-Samier A, Sibon I, Maire JP, Tison F. Long-term cure of Tolosa-Hunt syndrome after low-dose focal radiotherapy. 2005;45(4):389–91.

#### Author biography

**Ananda T M Kesavan**, Additional Professor

**Suma Premanandan**, Senior Resident

**Abdul N Basith**, Junior Resident

**Cite this article:** T M Kesavan A, Premanandan S, Basith AN. Tolosa-Hunt syndrome – A case of treatable headache. *IP Int J Med Paediatr Oncol* 2021;7(3):167-169.